

## HEPATOPROTECTIVE ACTIVITY OF *COCHLOSPERMUM TINCTORIUM* AGAINST CARBON TETRACHLORIDE INDUCED HEPATOTOXICITY IN RATS

OLUSEYI ADEBOYE AKINLOYE<sup>1,\*</sup>, AKINRINADE GEORGE AYANKOJO<sup>1</sup>,  
MOSHOOD OLAJIRE OLANIYI<sup>2</sup>

<sup>1</sup>Department of Biochemistry, College of Natural Science, University of Agriculture,  
P.M.B 2240, Abeokuta, Ogun-State, Nigeria

<sup>2</sup>Department of Veterinary Pathology, College of Veterinary Medicine,  
University of Agriculture, P.M.B 2240, Abeokuta, Ogun-State, Nigeria

(Received October 17, 2011)

The present study examines the potential hepatoprotective action of methanolic extract of *Cochlospermum tinctorium* leaf on carbon tetrachloride-induced liver damaged in rats. Forty rats divided into four groups (group 1 – control; group 2 – CCl<sub>4</sub> induced; group 3 – CCl<sub>4</sub> + *C. tinctorium* extract (200 mg/kg); group 4 – CCl<sub>4</sub> + prednisolone (standard anti-inflammatory drug) of ten rats in each were used. Administration of CCl<sub>4</sub> induced hepatic damage in rats, as evidenced by a significant ( $p < 0.05$ ) increase in the levels of serum glutamate pyruvate transaminase SGPT, serum glutamate oxaloacetate transaminase SGOT, cholesterol and bilirubin levels. The level of malondialdehyde MDA (an index of oxidative stress) was also higher in the CCl<sub>4</sub> group, when compared to other groups. However, administration of methanolic extract of *C. tinctorium* (200 mg/kg) after CCl<sub>4</sub> administration (group 3) brought a significant ( $p < 0.05$ ) reduction in values of these parameters compared to the CCl<sub>4</sub> treated group (group 1). The potential hepatoprotective activity of the extract was also demonstrated by its regenerative action on some damaged liver tissues, as evidenced by the histopathological studies of the representative liver sample of group 3 rats' liver section, which showed hepatic regeneration, with no visible pathology. This study therefore showed the potential of the *C. tinctorium* leaf extract to decrease the levels of serum markers enzymes, indicating the protection of hepatic cells, and to confer some levels of protection against CCl<sub>4</sub> induced hepatocellular injury.

**Key words:** Hepatoprotective, *Cochlospermum tinctorium*, Carbon tetrachloride, rats.

### INTRODUCTION

*Cochlospermum tinctorium* (*Cochlospermaceae*) is a bushy savannah plant, commonly found in fallow farms across northern Nigeria. It is a shrub that grows up to 10 m high. The leaves are alternate, palmate lobed, with stipules. The

\*Corresponding author (Email: oaakin@yahoo.com; phone: +2348030824063)

inflorescence consists of bright yellow flowers that are regular or slightly irregular and borne in racemes or panicles. Fruits are elongated 3–5 valve capsules containing seeds which are embedded in cotton foam (1). Its local/vernacular names include “Oja Ikoko”/’Sewutu’ (Yoruba), ‘Obazi’/’Abanzi’ (Igbo) and “Rawaya”/’Kyamba’ (Hausa). Decoctions of the whole roots have been reported to be used as remedy for gonorrhoea, jaundice, gastrointestinal diseases, helminthes and bilharzias infestations, as well as for the management of epilepsy (2–5). Togola *et al.* (6) have also reported the antimicrobial properties of *Cochlospermum tinctorium*. Recently, anticonvulsant properties and pharmacological evidence on the folkloric use of *Cochlospermum tinctorium* was reported (7–9). To the best of our knowledge, much of the published data focused on the properties of the *Cochlospermum tinctorium* root bark extract. Thus, the objective of the present study was designed to test the hepatoprotective activity of the methanolic extract of plant leaf against carbon tetrachloride induced liver damage in rats.

## MATERIALS AND METHODS

### PLANT MATERIALS AND PREPARATION OF THE METHANOLIC EXTRACT

Leaves of *Cochlospermum tinctorium* were collected from a local garden in Abeokuta, Nigeria. They were identified and authenticated by Dr. Aworinde D. O. (a plant taxonomist/anatomist) of the Department of Biological Sciences, University of Agriculture, Abeokuta, Nigeria. Some voucher specimen number was submitted to the authority for future references.

The leaves were washed with water, then allowed to air dry for 5 days and dried in an oven below 50°C, until a constant weight was obtained. The dried leaves were pulverized with a blender into a fluffy mass (fine powder); 200 g of powdered leaves were exhaustively extracted with 400 ml of 80% methanol (MeOH) by simple percolation (cold extraction) for five days. The extraction was repeated three times, to ensure that the extractable component has been fully removed from the plant material. The extracts were pooled together, filtered and concentrated in vacuum at 40°C, using a rotator evaporator, then about 12.5 g of crude methanol extract was obtained and subsequently referred to as *Cochlospermum tinctorium* methanolic leaf extract (CTMLE).

### ANIMALS

Forty white albino rats of either sex, weighing 150–180 g, purchased from the animal house of the Department of Veterinary Anatomy, University of Ibadan, Nigeria were used in this study. They were housed in iron cages under hygienic and standard environmental conditions (28±2°C, humidity 60-70%, natural 12 hr

light/dark cycle). They were allowed free access to laboratory diet (Ladokun and sons feeds, Nigeria Ltd) and water. They were allowed to acclimatize for two weeks. The rats were handled with care, according to the *Guide for the Care and Use of Laboratory Animals Manual*. All experimental protocols were approved by the Departmental animal ethics committee.

#### CHEMICALS AND REAGENTS

The carbon tetrachloride used by us was manufactured by May and Baker Ltd, Dagenham, England. Teco Diagnostic kits (Lakeview Ave. Anaheim, USA) were used for the analysis of biochemical parameters. All the other chemicals were of analytical grades.

#### PHYTOCHEMICAL SCREENING

The CTMLE was subjected to various phytochemical tests, in order to identify the constituent secondary metabolites using standard methods, as described by Harborne (10), Sofowora (11), and Trease and Evans (12).

#### EXPERIMENTAL DESIGN FOR HEPATOPROTECTIVE ACTIVITY

The rats were randomly divided into four groups of ten each. The hepatoprotective activity of plant extracts was tested using the CCl<sub>4</sub> model. Carbon tetrachloride hepatotoxicity was induced in rats according to the method of Rao *et al.* (13, 14), with slight modifications. Group I (normal control) received only food and water. Group II (induction control) was given a single intraperitoneal dose of 2 mg/kg CCl<sub>4</sub>. Group III received CCl<sub>4</sub> followed by oral administration of CTMLE at the dose of 200 mg/kg b.wt as a fine suspension made by adding sorbitol. Group IV received CCl<sub>4</sub> and then prednisolone (standard anti-inflammatory drug).

The experiment was carried out as per the guidelines of committee for the purpose of control and supervision of experiment on animal care and handling. The protocol conforms to the guidelines of the National Institute of Health (NIH).

#### ASSESSMENT OF HEPATOPROTECTIVE ACTIVITY

In the present study, the hepatoprotective activity was estimated biochemically and histopathologically. After a week administration/treatment, the animals were dissected under diethylether anesthesia. Blood from each rat was withdrawn by cardiac puncture into non-heparinized tubes, allowed to clot for 30 minutes at room temperature. Serum was separated by centrifugation at 3000 rpm for 15 min. The separated sera were used for the estimation of some biochemical parameters.

The level of malondialdehyde (MDA) produced was estimated by the double heating method of Draper and Hadely (15). Briefly, 1.0 ml of 100 g/L trichloroacetic (TCA) solution was added to 0.2 ml serum, placed in a water bath for 10 min. After cooling in tap water, the mixture was centrifuged at 1000 rpm for 10 min and 0.5 ml of the supernatant added to 0.5 ml of 6.7 g/L thiobarbituric acid solution in a test tube and placed in a boiling water bath for 15 min. The solution was then cooled under tap water and its absorbance measured at 532 nm (using a Shimadzu UV-VIS 1610 Tokyo Spectrophotometer). The concentration of MDA was calculated by the absorbance coefficient of MDA-TBA complex  $1.56 \times 10^5 \text{ cm}^{-1}\text{m}^{-1}$ . Serum alanine aminotransferase (ALT/SGPT) and aspartate aminotransferase (AST/SGOT) were determined according to the method of Reitman and Frankel (16), while cholesterol, bilirubin, urea and glucose levels were measured using the Teco reagent diagnostic kit. Protein concentration was determined by the method of Lowry *et al.* (17).

For histopathological studies, liver from each animal was removed after dissection and preserved in Bouin fluid (picric acid+formalin+acetic acid). Then, representative blocks of liver tissue from each lobe were taken and processed for paraffin embedding, using the standard microtechnique (18). Section (5  $\mu\text{m}$ ) of liver stained with hematoxylin and eosin was observed microscopically and photographed (Olympus, CS21) for histopathological studies.

#### STATISTICAL ANALYSIS

The results of biochemical analysis were expressed as mean  $\pm$  standard error of mean (Mean  $\pm$  S.E.M). The control and treatment groups were compared by using one-way analysis of variance (ANOVA). Differences were detected by the Turkey-Kramer multiple comparison test. The level of significance was taken at probability less than 5%.

#### RESULTS

The present study attempted to show the potential hepatoprotective activity of crude methanol leaf extract of *Cochlospermum tinctorium* in carbon tetrachloride induced hepatotoxicity. The *Cochlospermum tinctorium* leaf extract was found to contain saponins, flavonoids, tannins and alkaloids.

The results of CTMLE on some biochemical parameters used as basis for the hepatoprotective index at a dose of 200 mg/kg on rats intoxicated with  $\text{CCl}_4$  are resumed in Table 1.

Table 1

Effects of methanolic extract of *Cochlospermum tinctorium* on various biochemical parameters in rats with carbon tetrachloride induced hepatotoxicity

Groups	MDA (mmol/mL)	SGOT (U/L)	SGPT (u/L)	Cholesterol (mg/dL)	Bilirubin (mg/dL)	Urea (mmol/L)	Glucose (mg/dL)	Protein (mg/dL)
I	1.9 ± 0.3 <sup>a</sup>	31.1 ± 0.51 <sup>a</sup>	16.8 ± 0.57 <sup>a</sup>	110.3±1.12 <sup>a</sup>	0.61 ± 0.04 <sup>a</sup>	6.45±1.01 <sup>a</sup>	90.3 ± 1.7 <sup>a</sup>	4.43±0.9
II	5.8 ± 0.3 <sup>b</sup>	75.42 ± 0.63 <sup>b</sup>	29.2 ± 0.91 <sup>b</sup>	232.3±1.03 <sup>b</sup>	1.44 ± 0.11 <sup>b</sup>	8.74±0.90 <sup>b</sup>	93.8 ± 2.1 <sup>a</sup>	0.91±0.3
III	2.3 ± 0.6 <sup>a</sup>	42.6 ± 1.2 <sup>c</sup>	18.6 ± 0.61 <sup>a</sup>	119.1±1.23 <sup>a</sup>	0.87± 0.04 <sup>a</sup>	6.70±1.01 <sup>a</sup>	89.18 ± 0.97 <sup>a</sup>	2.24±0.5
IV	2.1 ± 0.3 <sup>a</sup>	37.1 ± 1.1 <sup>a</sup>	17.1 ± 0.49 <sup>a</sup>	105.6±1.02 <sup>a</sup>	0.82±0.08 <sup>a</sup>	6.50±0.98 <sup>a</sup>	92.41 ± 2.1 <sup>a</sup>	2.130±0.5

Values with different superscript along the same column are significantly different at  $p < 0.05$ . The table also shows a comparison of the CTMLE effects among the untreated (normal control), carbon tetrachloride treated (induced control), extract treated group and standard drug treated groups of rats. Data were represented as Mean ± Standard Error of Mean (M ± SEM). The results were analyzed statistically by one-way analysis of variance (ANOVA), followed by Turkey's test using SPSS 11.5 for window Software.  $P < 0.05$  was regarded as statistically significant.

It was observed that the CCl<sub>4</sub> group significantly increased the serum level of SPGT (5.75%), SGOT (41.5%), bilirubin (42.4%) and cholesterol when compared to the control group (group 1). However, the plant extract exhibited a significant protection against CCl<sub>4</sub> induced liver injury, as expressed by the reduction in toxin mediated rise in SGPT, SGOT and cholesterol level of rats. There was no statistical significant change in the blood glucose level of rats among all groups. The level of MDA was significantly higher in CCl<sub>4</sub> intoxicated rats by 32.7%, in comparison to the normal control group; this is an indication for lipid peroxidation of hepatic cells. Once administered to the CCl<sub>4</sub> intoxicated rats, the extract improved the level of peroxidation by reducing the amount of MDA. The results showed a significant decrease in MDA levels by 39.7%, when compared to CCl<sub>4</sub>-intoxicated rats. The value of MDA was close to that of the control group 1.

The results of histopathological studies also provided supportive evidence for biochemical analysis. For instance, histology of liver section of control animal (group 1) exhibited normal hepatic cells, each with well defined cytoplasm, prominent nucleus and nucleolus with well revealed central vein (Plate 1), whereas that of the CCl<sub>4</sub> intoxicated group animal showed complete loss of hepatic architecture with centrilobular hepatic necrosis fatty changes, vacuolization and sinusoid congestion (Plate 2). Treatment with methanol extract of *C. tinctorium* showed a moderate activity of protecting the liver cells against CCl<sub>4</sub> injury. The liver session of CTMLE treated group showed evidence of regeneration. The severity of degenerative changes in tubules was lower than in CCl<sub>4</sub> untreated group (Plate 3). However, test results in the CCl<sub>4</sub> + Prednisolone group were quite comparable to the control (Plate 4).

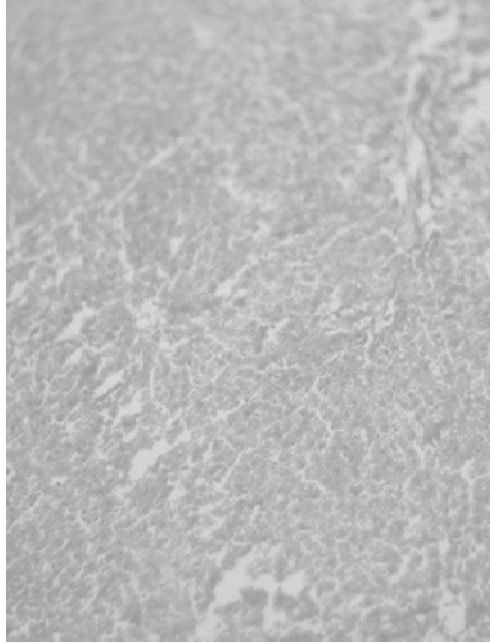


Plate 1 – Section of the liver tissue showing normal hepatocytes (control) x400.

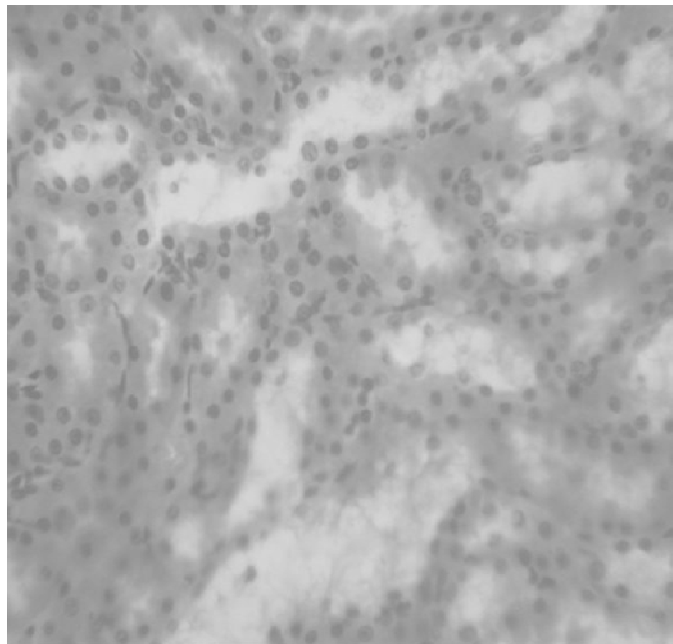


Plate 2 – Total loss of hepatic architecture with centrilobular hepatic necrosis fatty changes, vacuolization and congestion of sinusoids ( x 400).

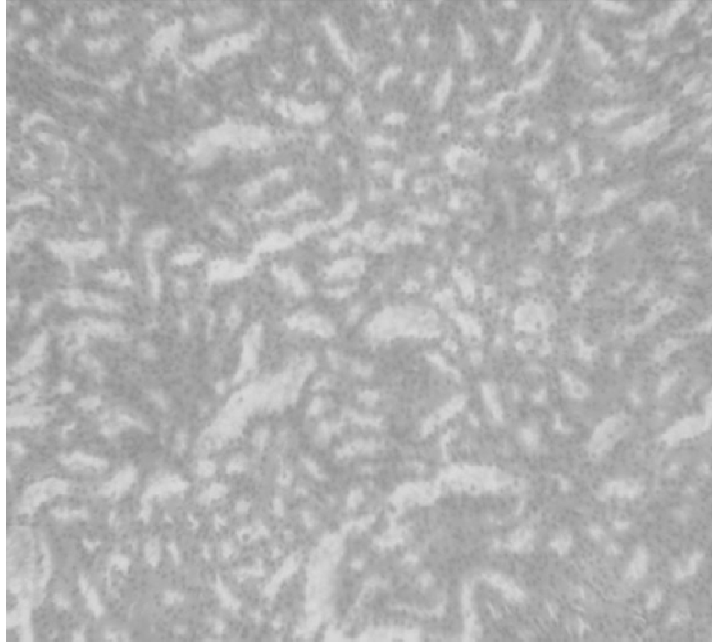


Plate 3 – Liver section of CTMLE treated group with evidence of regeneration (x 400).

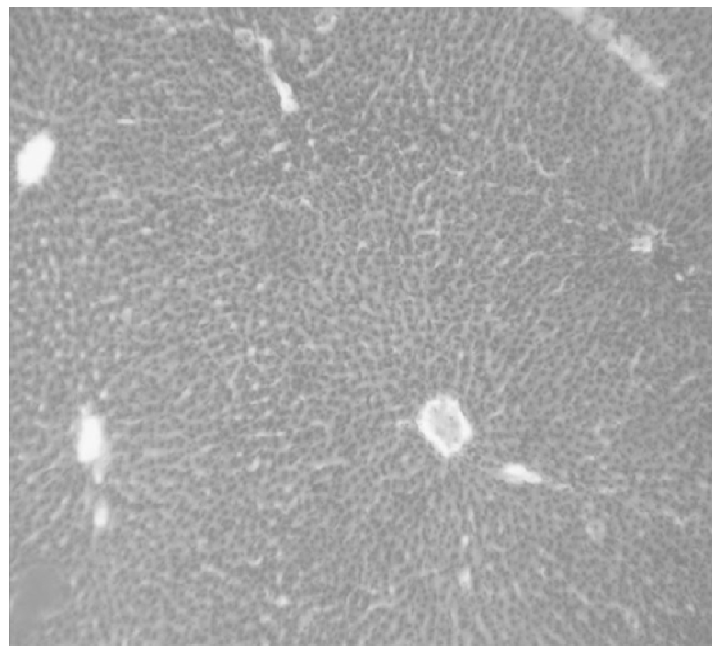


Plate 4 – CCl<sub>4</sub> + Prednisolone treated group with architecture relatively comparable to the control (x 400).

## DISCUSSION

The experimental induction of liver damage by CCl<sub>4</sub> in this study was adopted because CCl<sub>4</sub> has been known to catabolise free radical-induced lipid peroxidation, damaging the membranes of the liver cells and organelle, causing swelling and necrosis of hepatocytes, and resulting in the release of cytosolic enzymes (ALT, AST AP and GGT) into the circulating blood (19, 20). Also, prednisolone was used as a standard/reference drug or positive control, because it is known to be a hepatic curative agent through its modulatory anti-inflammatory actions on hepatic disorders irrespective of the cause.

The study demonstrates that single dose of CCl<sub>4</sub> injection produced elevated levels of SGPT, SGOT and cholesterol; an increase in bilirubin and decrease in protein was also found, which is in good agreement with the results of Etuk *et al.* (8). Many authors have reported hepatoprotective properties of some medicinal plants, such as *Cassia tora* (21), *Phyllanthus amarus* (22), *Zizyphus Mauritian* (23). However, liver damage with CCl<sub>4</sub> is a commonly used model for the screening of hepatoprotective drugs (24). To the best of our knowledge, the reviewed literature showed that no research has been reported on hepatoprotective properties of leaves. The present biochemical and histopathological analysis of our plant extract showed a good development in ameliorating carbon tetrachloride-induced damaged liver cells. The rise in serum levels of AST, ALT and cholesterol have been attributed to the damaged structural integrity of the liver, because they are located in the cytoplasm and are released into circulation after cellular damages. This is in line with the reports of Sallie *et al.* (25), and Ashan *et al.* (26), which show that, when administered to rats, chemicals or drugs often induce hepatotoxicity by metabolic disturbance and activation. For instance, CCl<sub>4</sub> is known to be metabolically activated by the cytochrome P-450 dependent mixed oxidase in the endoplasmic reticulum to form trichloromethyl radicals (CCl<sub>3</sub>), which combined with cellular lipids and proteins in the presence of oxygen to induce lipid peroxidation (27). Treatment with *C. tinctorium* methanol leaves extract recovered the injured liver to normal after a week administration at a dose of 200 mg/kg body weight, which indicates its potential as anti-hepatoprotective agent.

The ability of *C. tinctorium* extract to reduce the level of peroxidation could be attributed to the presence of flavonoids, which have been reported to possess anti-oxidant activity which is presumed to be responsible for the inhibitory effect on several enzymes, including those involved in arachidonic acid metabolism (13, 14).

## CONCLUSIONS

From the overall results, it could be inferred that *C. tinctorium* has hepatoprotective activity and it was assumed that it confers hepatoprotection probably as a result of the presence of both enzymic and non-enzymic antioxidants



that could bring about free radical suppressing activity. Meanwhile, work is in progress on other possible protective mechanisms, such that it may lend pharmacological/scientific credence to the ethno-medical claims of the use of this plant in the management of ailments.

#### REFERENCES

1. Tijjani MB, Bello IA, Aliyu AB, Olurische T, Maidawa SM, Habila JD, Balogun EO, *Phytochemical and Antibacterial studies of root extract of Cochlospermum tinctorium A. Rich (Cochlospermaceae)*, **Res. J. Med. Plt.**, **3**, 16–22 (2009).
2. Mann A, Gbate M, Umar AN. *Phytomedicine*, in: **Medicinal and Economic plants of Nupe Land**, Jube EA, Evans, eds, Bida, Nigeria, 2003, p. 64.
3. Chevallier A, *Medicinal Plants*, in: **The Encyclopedia of Medicinal plants**, Chaykin DK, Wiley J, eds, New York, USA, 1996, p. 232.
4. Burkill HM, *Plants of Economic importance*, in: **The useful plants of West Tropical Africa**, Davies C, Royal Botanical Garden, Kew, 2000, p. 387.
5. Traore M, Guiguemde A, Yago I, Nikiema JB, Tinto H, Dakuyo ZP, Quedraogo JB, Guissou IP, Guiguemde TR, *Investigation of antiplasmodial compounds from two plants, Cochlospermum tinctorium A. Rich and Gardenia sokotensis*, **Afr. J. Tradit. Comp. Alt. Med.**, **4**, 34–41 (2006).
6. Togola A, Diallo A, Dembele S, Barsett H, Paulsen BS, *Ethnopharmacological survey of different buses of some medicinal plants from Mali (West Africa) in the region Doila, Kolokani and Siby*, **J. Ethnobiol and Ethnomedicine**, **1**, 1–7 (2005).
7. Maiha BB Magaji MG, Yaro AH, Hamza AH, Ahmed SY, Magaji RA, *Anticonvulsant studies on Cochlospermum tinctorium and Paullina pinnata extracts in laboratory animal*, **Nig. J. Pharm. Sci.**, **8**, 102–108 (2009).
8. Etuk EU, Francis UU, Garba I, *Regenerative action of Cochlospermum tinctorium aqueous root extract on experimentally induced hepatic damage in rats*, **Afr. J. Biochem. Res.**, **1**, 001–004 (2009).
9. Magaji MG, Shehu A, Musa AM, Sani MB, Yaro AH, *Pharmacological evidence on the folkloric use of Cochlospermum tinctorium A Rich in the management of diarrhea*, **Int'l. J. Pure and Appl. Sci.**, **1**, 14–20 (2010)
10. Harborne JB, *Phytochemical Methods*, in: **A guide to modern techniques of plant analysis**, Chapman and Hall, eds, New Fetter Lane, London, 1984, pp. 149–188.
11. Sofowora A, *Herbal Plants*, in: **Medicinal plants and traditional medicine in Africa**, Ajagbo PO, ed, Spectrum Books Ltd, Ibadan, Nigeria, 1993, pp. 10–78.
12. Trease GE, Evans WC, *Phytomedicine*, in: **Pharmacognosy**, Stock R, Rice CB, eds, Tindale, London, 1989, p. 89.
13. Rao GMR, Chandana P, Palpu AS, *Hepatoprotective effects of rubiadin, a major constituent of Rubia cordifolia (Linn)*, **J. Ethnopharmacol.**, **103**, 484–490 (2006a).
14. Rao NV, Prakash KC, Kumar SMS, *Pharmacological investigation of Cardiospermum halicacabum (Linn) in different animal models of diarrhea*, **Ind. J. Pharmacol.**, **38**, 346–349 (2006b).
15. Draper HH, Hadley M, *Malondialdehyde determination as index of lipid peroxidation*, **Methods Enzymol.**, **186**, 421–43 (1990).
16. Reitman S, Frankel S, *Hepatic disorders*, **Am. J. Clin. Pathol.**, **28**, 53–56 (1957).
17. Lowry OH, Rosebrough, NJ, Randall, RJ, *Protein measurement with the Folin phenol reagent*, **J. Biol. Chem.**, **193**, 265–272 (1951).
18. Galigher AE, Kozloff EN, in: **Essentials of practical Micro Technique**, Lea and Febiger, 2<sup>nd</sup> ed., New York, 1976, p. 121.
19. Abdel-Hamid NM, *Diphenyl dimethyl bicarboxylate as an effective treatment for chemical treatment for chemical-induced fatty liver in rats*, **Afr. J. Biomed. Res.**, **9**, 77–81 (2006).

20. Venukumar MR, Latha MS, *Hepatoprotective effect of the methanolic extract of Curculigo orchoides in CCl<sub>4</sub>-treated male rats*, **Int'l J. Pharmacol.**, **5**, 45–50 (2009).
21. Rajan AV, Shanmugavalli C, Sunitha G, Umashanka V, *Hepatoprotective effect of Cassia tora on carbon tetrachloride-induced liver damage in albino rats*, **Ind. J. Sci. and Tech.**, **2**, 41–44 (2009)
22. Pramyothin P, Ngamtin C, Pongshompoo S, Chaichantipynta C, *Hepatoprotective activity of Phyllanthus amarus extract in ethanol treated rats: in vivo and in vitro studies*, **J. Ethnopharmacol.**, **98**, 351–358 (2003).
23. Dahiru D, Williams ET, Nadro MS, *Protective effect of Zizyphus mauritianna leaf extract on carbon tetrachloride-induced liver injury*, **J. Biotechnol.**, **4**, 1177–1179 (2005).
24. Slater TF, *Biochemical mechanism of liver injury*, in: **Tissue Biochemistry**, Russel TE, ed., Academic Press, London, 1965, p. 56.
25. Sallie R, Tredger JM, Williams R, *Drug and the liver. Part 1. Testing liver function*, **Biopharm. Drug Disp.**, **12**, 251–259 (2005).
26. Ashan R, Islam KM, Musaddik A, Haque E, *Hepatoprotective activity of methanol extract of some medicinal plants against carbon tetrachloride induced hepatotoxicity in albino rats*, **Global J. Pharmacology**, **3**, 116–122 (2009).
27. De Groot H, Nell T, *The critical role of low steady state oxygen partial pressures in haloalkane free-radical mediated lipid peroxidation*, **Biochem. Pharmacol.**, **35**, 15–19 (1986).